

Influence of non-orthodontic intervention on digit sucking and consequent anterior open bite: a preliminary study

Boyen Huang¹, Carla Lejarraga², Christopher S. Franco³, Yunlong Kang⁴, Andrew Lee³, John Abbott³, Katsu Takahashi⁵, Kazuhisa Bessho⁵ and Pongthorn Pumtang-on⁶

¹School of Dentistry and Health Sciences, Charles Sturt University, Orange, NSW, Australia; ²Thumbsucking Clinic, Townsville, QLD, Australia; ³School of Medicine and Dentistry, James Cook University, Cairns, QLD, Australia; ⁴Department of Orthodontics, Melbourne Dental School, the University of Melbourne, Melbourne, VIC, Australia; ⁵Department of Oral and Maxillofacial Surgery, Graduate School of Medicine, Kyoto University, Kyoto, Japan; ⁶School of Biomedical Sciences, Charles Sturt University, Wagga Wagga, NSW, Australia.

Objectives: This study aimed to assess behavioural and occlusal outcomes of non-orthodontic intervention (NOI) in a sample of children, 4–12 years of age, in Australia, in order to establish clinical relevance. **Materials and methods:** Data from 91 patient records of 4- to 12-year-old children reporting a habit of digit sucking, from two clinics in north-eastern Australia, were de-identified and used. Each patient had been examined at two visits, separated by an interval of 4 months, using standard clinical procedures. **Results:** Of the 77 children who received a 4-month NOI, 69 (89.6%) had ceased their digit sucking habit by the end of the NOI period [$\chi^2 = 67.0$, degrees of freedom (d.f.) = 1, $P < 0.001$]. Of the 72 subjects who had front teeth, the number with anterior open bite decreased from 37 (51.4%) to 12 (16.7%) upon completion of NOI ($\chi^2 = 21.3$, d.f. = 1, $P < 0.001$). Among the 32 patients with a measurable overjet, the mean overjet was found to decrease from 4.2 ± 2.4 mm to 3.1 ± 1.9 mm after implementation of NOI ($t = 5.8$, d.f. = 31, $P < 0.001$). Children who received NOI were more likely to quit the digit sucking habit in the 4-month period ($P < 0.001$, OR = 51.8, 95% CI: 9.8–273.9) and were more likely to appear without anterior open bite at a 4-month recall ($P < 0.001$, OR = 30.0, 95% CI: 5.9–151.6). **Conclusions:** This study demonstrated clinical relevance of NOI on the cessation of a digit sucking habit, closure of anterior open bite and reduction of overjet. Further investigations are indicated.

Key words: Digit sucking, anterior open bite, non-orthodontic intervention, incisive papilla, orofacial myology, stomahesive wafer

INTRODUCTION

Digit sucking has been considered an adaptive behaviour in infants and toddlers as it delays the onset of boredom and provides a soothing effect¹. Although most children cease digit sucking at an early age¹, previous studies have reported that 20%² to 30%³ of children still maintain a digit sucking habit. Recently, some researchers suggested that the premature cessation of breastfeeding⁴ and implementation of bottle-feeding⁵ had an enhancing effect on the digit sucking habit. This prolonged habit could result in some medical and behavioural complications, such as intestinal parasitic infection⁶, lead poisoning⁷, digital deformity⁸, paronychia⁹ or chronic hair pulling¹⁰. Previous studies have also reported dental and maxillofacial sequelae of prolonged digit sucking, including anterior open bite¹¹, increased overjet^{11–13}, decreased

overbite^{11,13}, protrusive incisors¹³ and a larger ANB angle¹³ which at times indicated the development of craniofacial deformity¹⁴.

Some appliances have been developed to correct children's digit sucking habits^{15–20}, simultaneously with, or only for, malocclusions resulting from these habits^{15–17,21,22}. Most of these apparatuses were designed with a wire framework for either retention or arch expansion, or both^{15,17–22}, and a roller nestling up against the hard palate to diminish enjoyment and comfort from digit sucking^{15,17–20}. On the contrary, Levrini *et al.*¹⁶ flipped the palatal surface of aligners to discourage the sucking habit. Of further note, a tongue crib was also included in the device used by Kulkarni and Lau¹⁵ to prevent the tongue from thrusting through the gap of the anterior open bite. Although the appliances described above were effective in promoting the cessation of digit sucking¹⁸,

correction of anterior open bite²¹, or both concurrently, these management options were costly and required advanced techniques.

On the other hand, some studies have reported reductions in orthodontic relapse with the aid of orofacial myofunctional therapy^{23,24}. Stabilisation of the tongue position was one of the reasons for a decrease in overbite relapse^{23,24} because the stimulus of the tongue on the maxillary dental arch had a protective effect against the development of a crossbite¹⁹. Therefore, maintaining contact between the tongue and the palate is 'decisive for orthodontic and myofunctional therapy in mouth-breathing children'²⁵. When in a normal rest position, the tongue tip rests over the incisive papilla²⁶ which is a pear-shaped anatomical landmark located on the palatal mucosa posterior to the maxillary central incisors²⁷. This structure is relevant to rhythmic activity of the tongue muscles²⁸ and guidance of tongue elevation²⁹. As a result, an earlier paper suggested that tongue-thrusting patients should regularly place the tongue tip on the palatal rugae behind the upper central incisors, in order to improve the condition³⁰.

As digit sucking is associated with mouth-breathing³¹, and both oral habits contribute to similar malocclusions³², using the incisive papilla as a guide for the tongue–palate contact position might ameliorate malocclusions in children with a history of digit sucking. Of further note, the American Dental Association has suggested that offering praise for not sucking fingers is more suitable than scolding children to cease the habit³³. A non-orthodontic intervention (NOI), comprising guidance of the tongue position and behaviour shaping with positive reinforcement, was therefore developed. To guide the tongue to the correct rest position, a small, round piece of gelatin material was placed onto the palate³⁴. This inexpensive and reduced technique-oriented approach has been used in clinical practice by some orofacial myologists. We believe that only a recent study described this intervention which exclusively used adult samples with unreported oral conditions³⁴. No data related to the use of NOI to correct digit sucking in children have ever been reported. Hence, the aim of this study was to conduct a retrospective case–control investigation to assess behavioural and occlusal outcomes of NOI in a sample group of children in Australia, in order to establish clinical relevance.

MATERIALS AND METHODS

Before commencement of the study, appropriate ethics approval was obtained from the James Cook University (JCU) Human Research Ethics Committee (Ethics Approval Number: H4732). The study was conducted in full accordance with the World Medical

Association Declaration of Helsinki. This retrospective study used de-identified data extracted from the patient records of the JCU Dental Clinic in Cairns (Clinic C) and the Thumbsucking Clinic in Townsville (Clinic T), Australia. Informed consent, on behalf of the children, from the next of kin, carers or guardians was not required because the data were de-identified and anonymised and none of the patients was approached or identified. This was also approved by the JCU Human Research Ethics Committee. This case–control study considered those digit sucking children who presented with the dental type of anterior open bites as Cases, and the digit sucking children who did not show any type of anterior open bites were the Controls. Anterior open bites are classified into dental and skeletal types, and the latter requires more advanced diagnostics and management³⁵. Hence, the dental type of anterior open bites resulting from digit sucking was the target of this study. The factor of exposure in this preliminary study was NOI.

The size of the sample was calculated using Epi Info (Version 7; Centers for Disease Control and Prevention, Atlanta, GA, USA). Because the reported prevalence of anterior open bites amongst digit sucking children is 36%¹¹, we estimated that 61 subjects was the minimum number required. The estimation was made using two-sided significance of 5%, an explanatory power of 80% and a ratio of Controls to Cases of 1.8¹¹, with 40% of Controls and 80% of Cases with exposure. The exposure rates of Cases and Controls used in the calculation were estimated according to our observations in the clinic because no data have ever been reported. To account for incomplete information, data from all patients showing clinic attendance in 2011, 2012 or 2013 were screened. To be eligible for inclusion, a subject needed to report a current status of digit sucking within the age range of 4–12 years. Children ≥ 4 years of age were included because maintaining a digit sucking habit after 4 years of age indicated a need for referral to a speech therapist and an orthodontist³⁶. Individuals older than 12 years of age were excluded from this study because of an indication for orthodontic treatment after eruption of maxillary permanent canines at the age of 12 years³⁶. Patients reporting a past history or current status of orthodontic treatment or maxillofacial surgery were also excluded from the study. Furthermore, those children who failed to attend the recall examination were excluded from data analysis.

The NOI implemented in this study was mainly composed of guidance of the tongue position and behaviour shaping with positive reinforcement. To guide the tongue tip to rest close to the incisive papilla²⁶, a small hole-punched stomahesive wafer with a diameter of 5 mm was placed on and attached

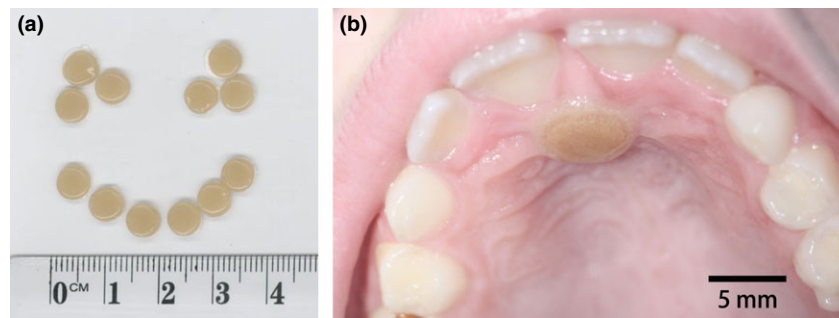


Figure 1. Stomahesive wafer spots used for non-orthodontic intervention (NOI). (a) Small hole-punched stomahesive wafer (diameter: 5 mm). (b) A stomahesive wafer spot attached to the incisive papilla (scale bar = 5 mm).

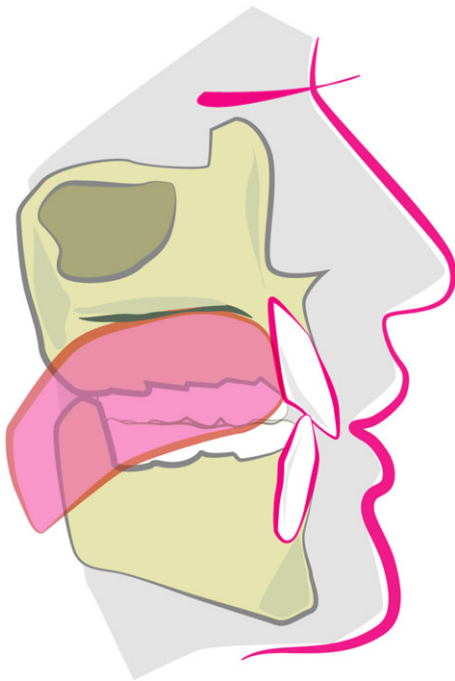


Figure 2. Schematic lateral view of the normal rest position of the tongue.

to the wiped incisive papilla (*Figure 1a,b*)³⁴. Children were trained to carry out the procedure three times per day with parents' supervision and assistance. Patients were then instructed to touch the spot of stomahesive wafer with the tongue tip. This helped to elevate the tongue for approximately 2 hours, three times a day, for each application of wafer spot in the correct rest position and encourage a lip seal (*Figure 2*). The spot of stomahesive wafer eventually melted and peeled off without being aspirated or causing harm. Indeed, this material has been safely and widely used in medical and dental practice^{37,38}, as well as in the food industry³⁴. Guidance of the tongue position through use of a stomahesive wafer spot was accompanied by a behaviour-shaping programme, which involved recording positive behaviour on reward charts and regular telephone calls from patients and parents to a trained orofacial myologist

and dental hygienist. Positive reinforcement has been recommended as a behaviour-shaping method for digit sucking children³³. In this study, a service fee was applied to the patients receiving the NOI.

The duration of the NOI in this preliminary study was 4 months. Those digit sucking children who did not receive NOI attended the clinic for two consecutive examinations with a recall interval of 4 months. The data collected from the de-identified patient files included age (years), gender (female/male), overjet (measured in mm), presence of anterior open bite (yes/no) and presence of digit sucking behaviour (yes/no). These included pre- and postintervention results for the patients who received NOI, and the results obtained from the first and second examinations of the subjects who did not receive NOI.

Data entry and statistical analyses were carried out using IBM SPSS Statistics (version 20.0; IBM Corporation, Somers, NY, USA). Data analysis included descriptive statistics (frequency distribution and cross-tabulation). First, pre- and postintervention data collected from the patients who received NOI were paired and examined for differences. Statistical significance for differences in the categorical variables (digit-sucking behaviour and anterior open bite) and the interval variable (overjet) were assessed using the McNemar test³⁹ and the paired-samples *t*-test⁴⁰, respectively. Second, 4-month recall data of all subjects, including children who did/did not receive NOI, were assessed using multivariate logistic regression⁴⁰. This method was applied to identify the individual contribution of variables studied (age, gender and exposure to NOI) in relation to cessation of the digit sucking habit and closure of anterior open bite. The level of two-sided significance for all statistical procedures was set at 5%.

RESULTS

A total of 578 patient records of children 4–12 years of age were de-identified and screened; these included 117 and 461 patients from Clinic T and Clinic C, respectively. A total of 115 patient records were excluded from data analysis because of incomplete

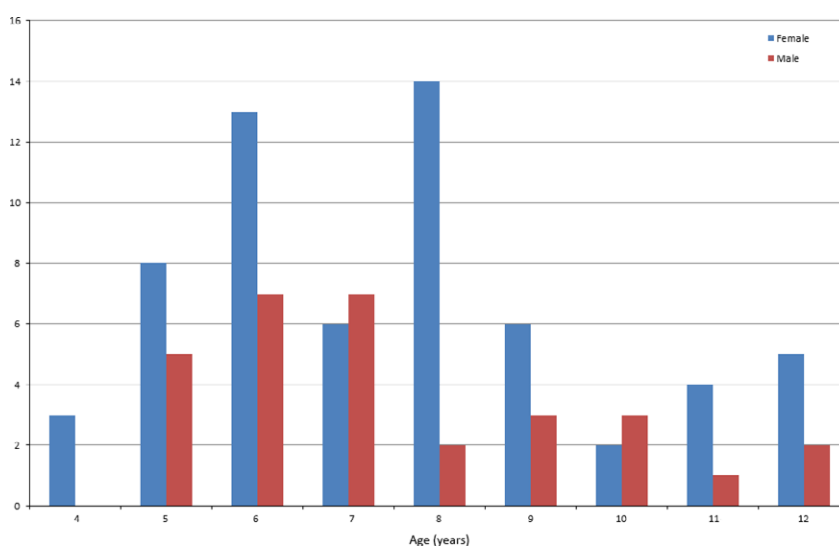


Figure 3. Frequency distribution of digit sucking habits, according to age and gender, in the study sample ($n = 91$); x axis: age groups; y axis: number of patients in each age group.

Table 1 Frequency distribution of anterior open bites, before and after non-orthodontic intervention (NOI), in the study sample ($n = 72$)

	After NOI		
	Without open bite	With open bite	Total
Before NOI			
Without open bite	34 (47.2%)	1 (1.4%)	35 (48.6%)
With open bite	26 (36.1%)	11 (15.3%)	37 (51.4%)
Total	60 (83.3%)	12 (16.7%)	72 (100.0%)

Values are given as n (%).

information. Another 162 subjects were excluded because of a previous history or current status of undergoing orthodontic treatment. Of the 301 patients with records that were valid, 91 (30.2%) reported a digit sucking habit in the first examination visit. Among the final sample of 91 children, 77 (84.6%) received NOI and 14 (15.4%) did not. *Figure 3* shows the frequency distribution of age and gender in this sample.

Of the 77 individuals who received NOI, 69 (89.6%) had ceased the digit sucking habit by the end of the 4-month programme [$\chi^2 = 67.0$, degrees of freedom (d.f.) = 1, $P < 0.001$]. Except for five children who had multiple missing front teeth according to their patient records, data on whether or not an anterior open bite was present remained attainable in 72 individuals. Among those, the number of patients showing an anterior open bite decreased from 37 (51.4%) to 12 (16.7%) after NOI ($\chi^2 = 21.3$, d.f. = 1, $P < 0.001$) (*Table 1*). The mean overjet decreased from 4.2 ± 2.4 mm to 3.1 ± 1.9 mm upon completion of NOI ($t = 5.8$, d.f. = 31, $P < 0.001$), among the 32 children with a measurable overjet.

Of the 91 subjects in the final sample, children who received NOI were more likely to cease their digit sucking habit by the end of the 4-month period ($P < 0.001$, OR = 51.8, 95% CI: 9.8–273.9) (*Table 2*). Age and gender were not related to continuation of the habit ($P \geq 0.648$). Among the 86 children with front teeth present, those who received NOI were more likely to present without an anterior open bite at the 4-month recall visit ($P < 0.001$, OR = 30.0, 95% CI: 5.9–151.6) (*Table 3*). Age and gender were not associated with the manifestation of an anterior open bite ($P \geq 0.358$). *Figure 4* shows a clinical case of a patient with a digit sucking habit and the consequent anterior open bite, before (*Figure 4a,b*) and after (*Figure 4c,d*) receiving NOI.

DISCUSSION

This is the first study to suggest a relationship between NOI and closure of anterior open bite. Approximately two-thirds of this study’s Cases, who previously sustained digit sucking-related anterior open bites, no longer presented with this type of malocclusion at the end of the 4-month NOI period. This indicated good efficacy for NOI on the correction of anterior open bites for patients 4–12 years of age. This was further confirmed by outcomes from the logistic regression model. Attachment of the stomahesive wafer spot onto the incisive papilla provided clear guidance for the tongue–palate contact position. Because of the sensation of a foreign body over the incisive papilla, the tongue tip is unable to resist the temptation to explore, and at times remove, the stomahesive wafer spot. Consequently, the tongue is elevated to a normal rest position. This position is relevant to the improvement of an anterior open bite²⁶ and tongue

Table 2 Frequency distribution and statistical analysis of digit sucking habits at the recall visit, according to age, gender and non-orthodontic intervention (NOI), in the study sample ($n = 91$)

Characteristic	Without digit sucking	With digit sucking	All	OR (95% CI)	<i>P</i>
Mean age (years)	7.2 ± 1.7	9.3 ± 3.1	7.6 ± 2.3	1.0 (0.7–1.4)	0.956
Gender					
Female	48 (78.7%)	13 (21.3%)	61 (67.0%)	1	0.648
Male	23 (76.7%)	7 (23.3%)	30 (33.0%)	0.7 (0.2–3.1)	
NOI					
With NOI	69 (89.6%)	8 (10.4%)	77 (84.6%)	1	<0.001*
Without NOI	2 (14.3%)	12 (85.7%)	14 (15.4%)	51.8 (9.8–273.9)	

Values are given as mean ± standard deviation, *n* (%) or OR (95% CI).

* $P < 0.001$.

Table 3 Frequency distribution and statistical analysis of anterior open bites at the recall visit, according to age, gender and non-orthodontic intervention (NOI), in the study sample ($n = 86$)

Characteristic	Without open bite	With open bite	All	OR (95% CI)	<i>P</i>
Mean age (years)	7.2 ± 1.9	8.7 ± 2.9	7.6 ± 2.3	0.9 (0.6–1.2)	0.358
Gender					
Female	43 (72.9%)	16 (27.1%)	59 (68.6%)	1	0.613
Male	19 (70.4%)	8 (29.6%)	27 (31.4%)	0.7 (0.2–2.6)	
NOI					
With NOI	60 (83.3%)	12 (16.7%)	72 (83.7%)	1	<0.001*
Without NOI	2 (14.3%)	12 (85.7%)	14 (16.3%)	30.0 (5.9–151.6)	

Values are given as mean ± standard deviation, *n* (%) or OR (95% CI).

95% CI, 95% confidence interval; OR, odds ratio.

* $P < 0.001$.

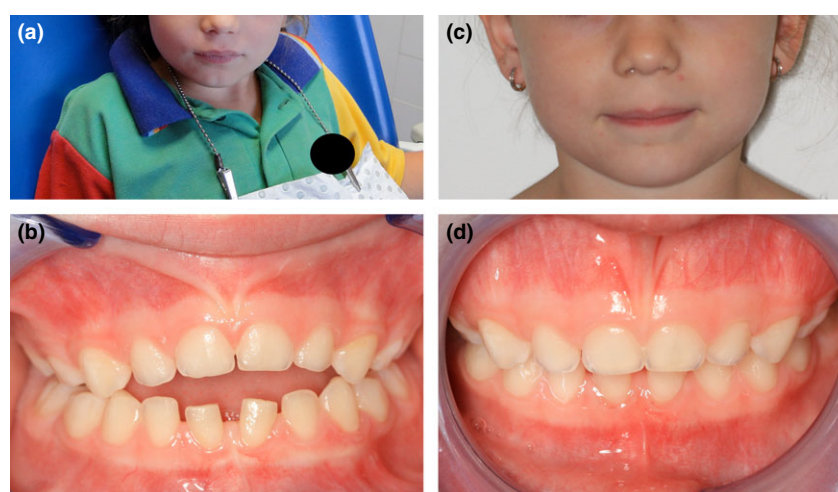


Figure 4. Extra-oral and intra-oral photographs of a child with a digit sucking habit and a consequent anterior open bite. (a) Frontal view of the lower face, before non-orthodontic intervention (NOI). (b) Intra-oral photograph showing the frontal view of the anterior open bite, before NOI. (c) Frontal view of the lower face, after NOI. (d) Intra-oral photograph showing the frontal view after NOI; closure of the anterior open bite was identified.

thrusting³⁰. A previous study demonstrated that the equilibrium of tooth position relied on a balance of pressure between the tongue and the lip⁴¹. As a torque depends on the length of the lever arm⁴², elevation of the rest position of the tongue from the incisal edge of maxillary incisors to the incisive papilla shortens the lever arm. This reduces the torque on the upper front teeth. Previous studies also reported a larger magnitude of pressure from the tongue to the upper incisors during either rest⁴³ or swallowing⁴⁴ in children with an anterior open bite. The causal relationship between

tongue pressure and anterior open bite remains controversial^{43,44}. However, a decreased torque on upper incisors from the tongue might allow the pressure from the lips to guide the teeth into moving downwards and backwards, resulting in closure of the anterior open bite. Reduced overjet found in children who received NOI also implied a backwards movement, or rotation of, the upper incisors.

On the other hand, this study suggests for the first time an association between NOI and cessation of the digit sucking habit. Approximately 90% of digit suck-

ing subjects quit the habit upon completion of the 4-month NOI period, indicating excellent efficacy of the intervention. Our results from the logistic regression model also confirmed this. The cessation of digit sucking after completion of NOI could further explain the reason why a majority of anterior open-bite cases were eliminated in this study. Indeed, spontaneous correction of an anterior open bite following cessation of the pacifier sucking habit has been reported⁴⁵. Owing to the sensation of a foreign body, the stomachesive wafer spot attached to the incisive papilla could have induced the tongue tip to touch the spot. This might have distracted the subjects from insertion of the thumb or other fingers into the mouth. This functions in a similar way to the roller utilised by a Bluegrass appliance²⁰. In addition to the distraction effect of the wafer, behaviour shaping with positive reinforcement, included in our NOI, could be another reason for the excellent efficacy attributed to cessation. Behaviour shaping with positive reinforcement has been recommended by the American Dental Association for managing digit sucking in children³³. Of further note, regular telephone calls from children and parents to a trained orofacial myologist and dental hygienist served as a reminder and form of support. These may have enhanced the effect of the NOI.

With encouraging outcomes reported, interpreting the results of this preliminary study, however, should take some research limitations into account. First, the nature of the sample used in this study might not be representative of the broader population of digit sucking children. Those patients and their parents or carers who came to the clinic with the chief complaint of digit sucking or consequent anterior open bites tended to have a motive of seeking 'a change'. Because improvement of a disorder or condition is highly related to the patients' initial motivation to change⁴⁶, the high efficacy of NOI in our study could partially have resulted from the children's and their family's motives to cease digit sucking and improve malocclusion. Those children who attended our clinics, but did not opt to receive NOI, may have missed the 4-month recall and consequently the valid number of unexposed subjects was smaller than the number of exposed subjects in this study. It is difficult to avoid sampling bias caused by patients' motivation in a clinical environment⁴⁷. Second, this study did not include a long-term recall plan. Consequently, the relapse rate of digit sucking and anterior open bite was not evaluated. Despite the fact that orthodontic treatment alone has shown a higher relapse rate of anterior open bites than a combination with orofacial myofunction therapy²⁴, future investigations in longitudinal changes of behavioural and occlusal outcomes are required to explore the long-term efficacy of NOI. Third, the sample used in this study was within an age range of 4–

12 years. Anterior open bites occurring within this age range are generally managed using interceptive orthodontic approaches, whereas patients older than 12 years of age would require orthodontic management to correct the malocclusion^{36,48}. Therefore, the outcomes of this study do not imply the superiority of NOI over orthodontic management for digit sucking patients with an anterior open bite. Moreover, this study does not suggest NOI to be a substitute for orthodontic treatment. Instead, NOI could be applied to children 4–12 years of age, presenting with digit sucking and consequent anterior open bites in areas where orthodontic services are unattainable, such as rural and remote areas. This may also apply when a child's behavioural issues or health conditions make it difficult for him or her to cope with regular orthodontic visits. As this study was a preliminary investigation, further studies are indicated.

CONCLUSIONS

This preliminary study has demonstrated satisfactory efficacy of NOI on the cessation of the digit sucking habit, closure of anterior open bite and reduction of overjet. NOI can be used on children, 4–12 years of age, presenting with digit sucking and consequent anterior open bite, in areas where orthodontic services are unattainable, such as in rural and remote areas, as well as when a child cannot cope with regular orthodontic visits as a result of behavioural issues or health conditions. Future investigations into relapse of habitual sucking, with or without malocclusion, are indicated.

Acknowledgements

The authors would like to show appreciation to those staff and students who helped in this project. In addition, the authors are indebted to Dr Mei-lan Chen for her assistance in preparation of electronic artwork.

Conflict of interest

There was not conflict of interests among the authors.

REFERENCES

1. Friman PC, Schmitt BD. Thumb sucking: pediatricians' guidelines. *Clin Pediatr* 1989 28: 438–440.
2. dos Santos R, Nayme J, Garbin A *et al.* Prevalence of malocclusion and related oral habits in 5- to 6-year-old children. *Oral Health Prev Dent* 2012 10: 311–318.
3. Köhler L, Holst K. Malocclusion and sucking habits of four-year-old children. *Acta Paediatr Scand* 1973 62: 373–379.
4. Fukumoto E, Fukumoto S, Kawasaki K *et al.* Cessation age of breast-feeding and pacifier use is associated with persistent finger-sucking. *Pediatr Dent* 2013 35: 506–509.
5. Yonezu T, Arano-Kojima T, Kumazawa K *et al.* Association between Feeding Methods and Sucking Habits: a Cross-

- tional Study of Infants in Their First 18 Months of Life. *Bull Tokyo Dent Coll* 2013 54: 215–221.
6. Sah R, Bhattarai S, Yadav S *et al*. A study of prevalence of intestinal parasites and associated risk factors among the school children of Itahari, Eastern Region of Nepal. *Tropical Parasitology* 2013 3: 140–144.
 7. Centers for Disease Control and Prevention (CDC). Childhood lead poisoning from commercially manufactured French ceramic dinnerware – New York City, 2003. *Morb Mortal Wkly Rep* 2004 53: 584–586.
 8. Srinivasan J, Hutchinson JW, Burke FD. Finger sucking digital deformities. *J Hand Surg Br* 2001 26: 584–588.
 9. Durdu M, Ruocco V. Clinical and cytologic features of antibiotic-resistant acute paronychia. *J Am Acad Dermatol* 2014 70: 120–126.e121.
 10. Byrd MR, Richards DF, Hove G *et al*. Treatment of early onset hair pulling as a simple habit. *Behav Modif* 2002 26: 400–411.
 11. Mistry P, Moles DR, O'Neill J *et al*. The occlusal effects of digit sucking habits amongst school children in Northamptonshire (UK). *J Orthod* 2010 37: 87–92.
 12. Luzzi V, Guaragna M, Ierardo G *et al*. Malocclusions and non-nutritive sucking habits: a preliminary study. *Prog Orthod* 2011 12: 114–118.
 13. Torgersbråten N, Linge L, Vandevska-Radunovic V. Oral habits in a group of consecutively treated orthodontic patients, using standardized video recordings for diagnosis. *Acta Odontol Scand* 2012 70: 635–640.
 14. Huang B, Takahashi K, Yamazaki T *et al*. Assessing anteroposterior basal bone discrepancy with the Dental Aesthetic Index. *Angle Orthod* 2012 83: 527–532.
 15. Kulkarni GV, Lau D. A single appliance for the correction of digit-sucking, tongue-thrust, and posterior cross bite. *Pediatr Dent* 2010 32: 61–63.
 16. Levrini L, Tettamanti L, Macchi A *et al*. Invisalign teen for thumb-sucking management. A case report. *Eur J Paediatr Dent* 2012 13: 155–158.
 17. Campbell P. Simultaneous correction of digital sucking habits and posterior crossbite with a combo appliance. *J Clin Orthod* 1984 18: 254–256.
 18. Baker C. The modified bluegrass appliance [to stop thumbsucking]. *Oral Health* 2001 91: 25–27.
 19. Ritto A, Leitão P. The lingual pearl. *J Clin Orthod* 1998 32: 318–327.
 20. Haskell B, Mink J. An aid to stop thumb sucking: the “Bluegrass” appliance. *Pediatr Dent* 1991 13: 83–85.
 21. Cozza P, Baccetti T, Franchi L *et al*. Treatment effects of a modified quad-helix in patients with dentoskeletal open bites. *Am J Orthod Dentofac Orthop* 2006 129: 734–739.
 22. Giuntini V, Franchi L, Baccetti T *et al*. Dentoskeletal changes associated with fixed and removable appliances with a crib in open-bite patients in the mixed dentition. *Am J Orthod Dentofac Orthop* 2008 133: 77–80.
 23. Weiss CE, van Houten JT. A remedial program for tongue-thrust. *Am J Orthod* 1972 62: 499–506.
 24. Smithpeter J, Covell D Jr. Relapse of anterior open bites treated with orthodontic appliances with and without orofacial myofunctional therapy. *Am J Orthod Dentofac Orthop* 2010 137: 605–614.
 25. Knösel M, Klein S, Bleckmann A *et al*. Coordination of tongue activity during swallowing in mouth-breathing children. *Dysphagia* 2012 27: 401–407.
 26. Artese A, Drummond S, Nascimento JMD *et al*. Criteria for diagnosing and treating anterior open bite with stability. *Dental Press J Orthod* 2011 16: 136–161.
 27. Ortman H, Tsao D. Relationship of the incisive papilla to the maxillary central incisors. *J Prosthet Dent* 1979 42: 492–496.
 28. van Willigen JD, Weijs-Boot J. Phasic and rhythmic responses of the oral musculature to mechanical stimulation of the rat palate. *Arch Oral Biol* 1984 29: 7–11.
 29. Jang S-J, Cha B-K, Ngan P *et al*. Relationship between the lingual frenulum and craniofacial morphology in adults. *Am J Orthod Dentofac Orthop* 2011 139: e361–e367.
 30. Jann H. Tongue thrusting as a frequent unrecognized cause of malocclusion and speech defects. *NY State Dent J* 1960 26: 72–81.
 31. Trawitzki LVV, Anselmo-Lima WT, Melchior MO *et al*. Breast-feeding and deleterious oral habits in mouth and nose breathers. *Braz J Otorhinolaryngol* 2005 71: 747–751.
 32. Harila V, Heikkinen T, Grön M *et al*. Open bite in prematurely born children. *J Dent Child* 2007 74: 165–170.
 33. American Dental Association (ADA). Thumb sucking and pacifier use. *J Am Dent Assoc* 2007 138: 1176.
 34. Moschik CE. *Influence of Orofacial Myology Therapy on Upper Inter canine Distance*. Graz: Medical University of Graz; 2013.
 35. Sassouni V. A classification of skeletal facial types. *Am J Orthod* 1969 55: 109–123.
 36. Emerich K, Wojtaszek-Slominska A. Clinical practice: later orthodontic complications caused by risk factors observed in the early years of life. *Eur J Pediatr* 2010 169: 651–655.
 37. Buchanan S, Jenkins CR. Riga-Fedes syndrome: natal or neonatal teeth associated with tongue ulceration. Case report. *Aust Dent J* 1997 42: 225–227.
 38. Gross E, Irving M. Protection of the skin around intestinal fistulas. *Br J Surg* 1977 64: 258–263.
 39. McNemar Q. Note on the sampling error of the difference between correlated proportions or percentages. *Psychometrika* 1947 12: 153–157.
 40. Altman D. *Practical Statistics for Medical Research*. London: Chapman and Hall; 1991.
 41. Thüer U, Sieber R, Ingervall B. Cheek and tongue pressures in the molar areas and the atmospheric pressure in the palatal vault in young adults. *Eur J Orthod* 1999 21: 299–309.
 42. Myers RL. *The Basics of Physics*. Westport: Greenwood Press; 2006.
 43. Taslan S, Biren S, Ceylanoglu C. Tongue pressure changes before, during and after crib appliance therapy. *Angle Orthod* 2010 80: 533–539.
 44. Yousefzadeh F, Shcherbaty V, King GJ *et al*. Cephalometric and electromyographic study of patients of East African ethnicity with and without anterior open bite. *Am J Orthod Dentofac Orthop* 2010 137: 236–246.
 45. Verrastro A, Stefani F, Rodrigues C *et al*. Occlusal and orofacial myofunctional evaluation in children with anterior open bite before and after removal of pacifier sucking habit. *Int J Orthod* 2007 18: 19–25.
 46. Castro-Fornieles J, Bigorra A, Martinez-Mallen E *et al*. Motivation to change in adolescents with bulimia nervosa mediates clinical change after treatment. *Eur Eat Disord Rev* 2011 19: 46–54.
 47. Avins AL. Can unequal be more fair? Ethics, subject allocation, and randomised clinical trials. *J Med Ethics* 1998 24: 401–408.
 48. Koch G, Poulsen S. *Pediatric Dentistry: A Clinical Approach*. Copenhagen: Munksgaard; 2001.

Correspondence to:

Boyen Huang,
 CSU School of Dentistry and Health Sciences,
 Leeds Parade,
 Orange, NSW 2800, Australia.
 Email: bhuang@csu.edu.au